

Full Length Research Paper

# Trisomy 21 in children born with anorectal malformation

Ashma Gupta<sup>1</sup>, A. S. Yadav<sup>2\*</sup>, Minakashee Sharma<sup>1</sup> and Ravi Sharma<sup>1</sup>

<sup>1</sup>Human Genetic Research Cum Counseling Centre, Government Medical College, University of Jammu, Jammu, India. <sup>2</sup>Department of Zoology, Human Cytogenetic Lab, Kurukshetra University, Kurukshetra-136119, India.

Accepted 3 November, 2013

**Cytogenetic analysis in 24 clinically diagnosed cases of anorectal malformation carried out using GTG banding techniques showed trisomy 21, the chromosomal abnormality of Down syndrome in 4 cases. Of the 4 cases, 3 were male children and 1 was female child and the remaining 21 cases had normal karyotype of a male or female. Four cases as were found possessing the karyotype of Down syndrome were phenotypically not having the clinical symptom of a typical Down syndrome. The study has been carried out for the first time jointly from the states of Haryana and J&K.**

**Key words:** Trisomy 21, anorectal malformation, karyotype.

## INTRODUCTION

Anorectal malformation is the congenital anomaly where the distal anus and the rectum are defective. This anomaly affects both the sexes and occurs in approximately 1 in 2500 to 1 in 5000 live births (Levitt and Pena, 2007; Cho et al., 2001). Anorectal malformation may have the genetic or environmental or the combination of both these factors as its cause. Association of trisomy 21 with anorectal malformation has often been reported in approximately 2% of the cases of Down syndrome (Black and Sherman, 1989; Hassink et al., 1996; Gupta et al., 1998; Torres et al., 1998). Besides trisomy 21 reported in 2% Down syndrome children having anorectal malformation, trisomy 13 and trisomy 18 have also been reported in the cases of anorectal malformation, but the frequency of both these trisomies have been found to be very low (Levitt and Pena, 2007).

In the present study, attempts have been made to find out the incidence of trisomy 21 in children born with anorectal malformation.

## MATERIALS AND METHODS

During two years of study (July 2009 to July 2011), 24 children in different age group (Table 1) presenting with anorectal malformation were taken up for chromosome study so as to rule out the

the chromosomal cause for the congenital anomaly, these 24 children had. Short term lymphocytes cultures were setup for all the 24 cases and in each case the chromosome study was carried out from well spread G-banded metaphase plates (Saebright, 1971). Some of the well spread G-banded metaphase plates in each case were selected for the preparation of their karyotype. Details of the results obtained are discussed.

## RESULTS

Of the 24 children born with anorectal malformation (Figure 1) as the congenital anomaly, majority were male 18/24 (75%) and the remaining 6/24 (25%) were female. Age group of these 24 children ranged between as low as 10 days to the maximum of 6 years. 50% (12/24) of these children were 1st in birth order, 37.5% (9/24) were 2nd in birth order while the remaining 12.5% (3/24) were either 3rd or 4th in birth order. All the 24 children were born to mothers below 30 years age and the paternal age in majority of the cases was less than 35 years. Excepting for 2, the remaining 22 children were born to the non-consanguineous couples (Table 1).

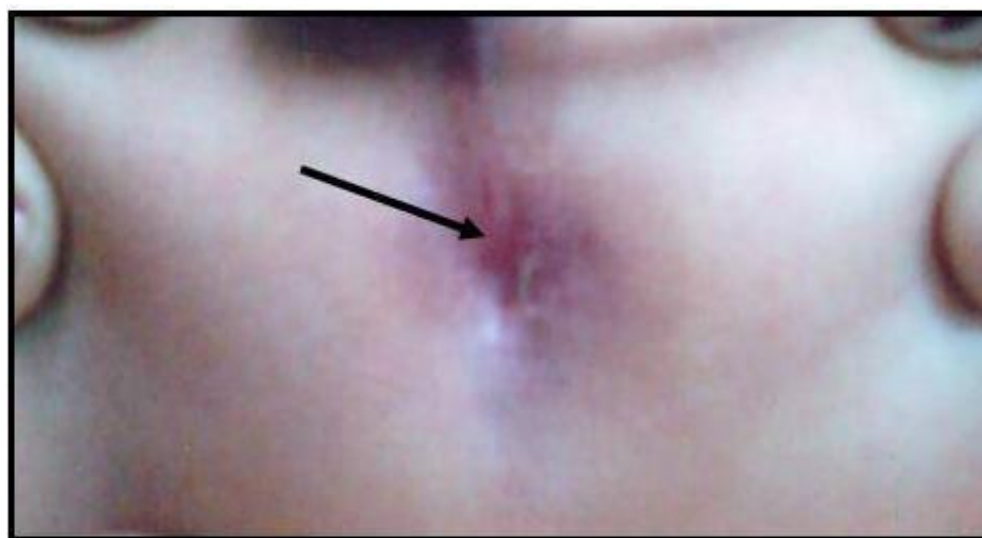
To rule out the chromosomal cause for the Anorectal Malformation, all the 24 children were subjected to chromosome study. Of the 24 children, 20 were found possessing the karyotype of a normal male or female whereas the remaining 4 children, had the karyotype of the Down syndrome showing trisomy 21. This chromosomal abnormality (+21) was detected in 3 male children

\*Corresponding author. E-mail: abyzkuk@gmail.com

**Table 1.** Details of 24 cases of anorectal malformation.

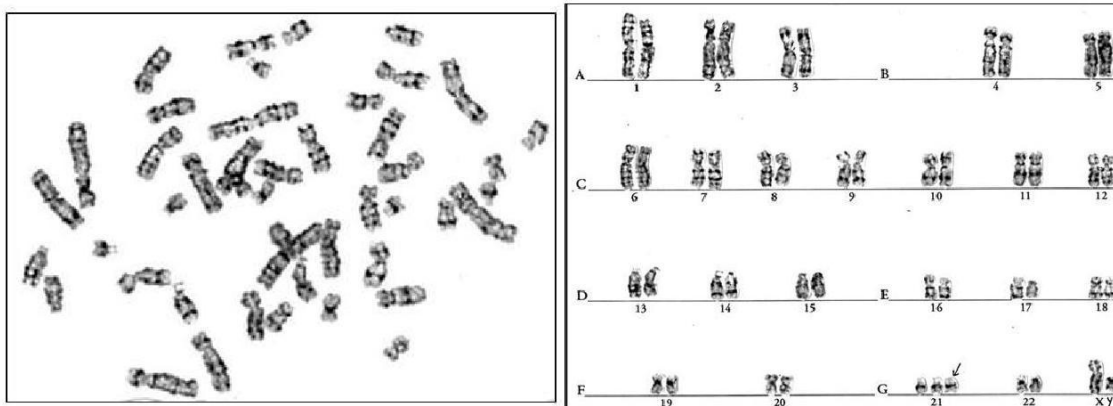
S/No.	Clinical diagnosis	Age (in years)	Birth order	Maternal age (in years)	Paternal age (in years)	Consanguinity	Result
1	ARM	1	2 <sup>nd</sup>	24	30	NC	46,XY
2	ARM	1.4	1 <sup>st</sup>	25	22	C	46,XY
3	ARM	1.2	4 <sup>th</sup>	30	35	NC	47,XY+21
4	ARM	3	1 <sup>st</sup>	23	42	NC	46,XY
5	ARM	1.4	1 <sup>st</sup>	20	27	C	46,XY
6	ARM	1.6	1 <sup>st</sup>	24	30	NC	47,XX+21
7	ARM	10 days	2 <sup>nd</sup>	23	29	NC	46,XY
8	ARM	2.6	1 <sup>st</sup>	21	25	NC	46,XX
9	ARM	5 months	2 <sup>nd</sup>	24	32	NC	46,XX
10	ARM	1	2 <sup>nd</sup>	23	29	NC	46,XY
11	ARM	6	2 <sup>nd</sup>	26	28	NC	46,XY
12	ARM	1	1 <sup>st</sup>	29	39	NC	46,XY
13	ARM	1.6	2 <sup>nd</sup>	26	27	NC	47,XY+21
14	ARM	2	3 <sup>rd</sup>	28	30	NC	46,XX
15	ARM	1.4	1 <sup>st</sup>	24	26	NC	46,XY
16	ARM	2	1 <sup>st</sup>	25	28	NC	46,XY
17	ARM	2.2	1 <sup>st</sup>	25	29	NC	47,XY+21
18	ARM	1	2 <sup>nd</sup>	28	32	NC	46,XX
19	ARM	1.5	3 <sup>rd</sup>	29	31	NC	46,XY
20	ARM	2.5	1 <sup>st</sup>	23	27	NC	46,XX
21	ARM	1.3	2 <sup>nd</sup>	27	33	NC	46,XY
22	ARM	1	1 <sup>st</sup>	24	26	NC	46,XY
23	ARM	2.6	1 <sup>st</sup>	25	29	NC	46,XY
24	ARM	1.8	2 <sup>nd</sup>	30	32	NC	46,XY

ARM = Anorectal Malformation; NC = non consanguineous; C = consanguineous.

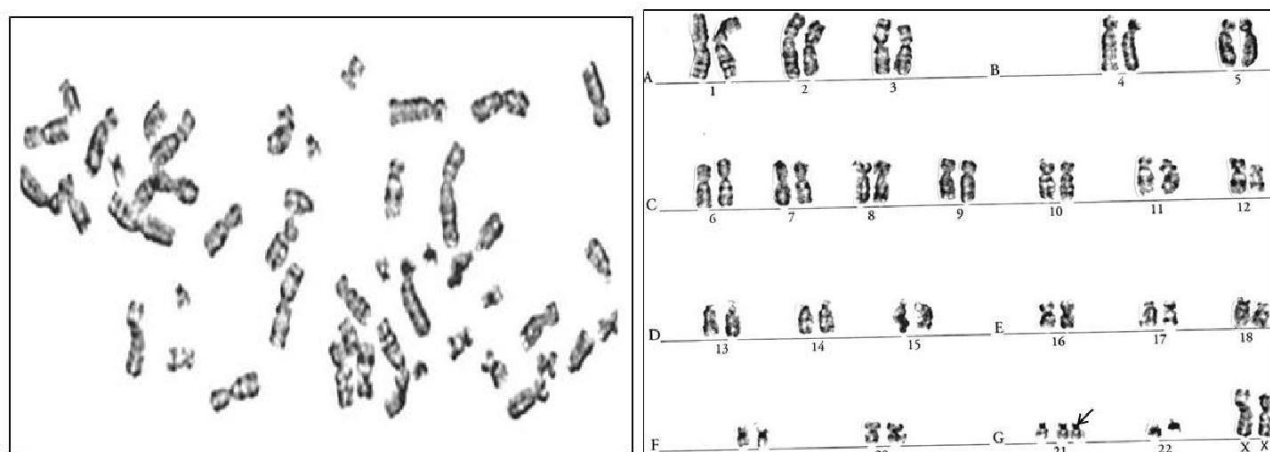
**Figure 1.** Anorectal malformation.

and one female child, (Figures 2 and 3). The incidence of trisomy 21 was about 17% in the 24 cases of Anorectal Malformation taken up for their chromosome study. Four

children where trisomy 21 was detected did not have the prominent features of the Down syndrome although they processed the karyotype of a Down syndrome.



**Figure 2.** GTG-banded karyotype of male baby with anorectal malformation showing trisomy 21.



**Figure 3.** GTG-banded karyotype of female baby with anorectal malformation showing trisomy 21.

## DISCUSSION

Different chromosomal abnormalities especially the numerical changes have been reported from the cases of Anorectal Malformation but the association of trisomy 21 with Anorectal Malformation is very well documented (Levitt and Pena, 2007; Cho et al., 2001; Gupta et al., 1998; Torres et al., 1998). The frequency of trisomy 21 in the cases of anorectal malformation has been reported to be nearly 2% (Cho et al., 2001; Torres et al., 1998).

During the present study, trisomy 21 has been reported in 4 out of 24 children of anorectal malformation. Of the 4 cases, 3 were males and 1 was female. With respect to the incidence of trisomy 21 in cases of anorectal malformation the present findings are not in agreement with earlier studies reporting trisomy 21 in 2 to 5% of the children born with anorectal malformation (Torres et al., 1998). Trisomy 21, the commonest human congenital anomaly, is the cause for Down syndrome, affecting 1 in 826 live births (Jayalakshamma et al., 2010). Trisomy 21

though reported in certain cases of Anorectal Malformation, is not always the chromosomal cause for Anorectal Malformation as it has been reported in 2 to 5% of Down Syndrome by earlier workers and to the tune of 17% in the present study, however, the study of literature shows that majority of Down syndrome do not have anorectal malformation suggesting thereby that trisomy 21 may cause anorectal malformation but it is not always responsible for this congenital anomaly. The study of the available literature shows that anorectal malformation is very common in the male sex and trisomy 21 in anorectal malformation is also common amongst the males suggesting thereby that anorectal malformation as well as trisomy 21 is more the problem of males than females, however to make this statement more acceptable further studies all throughout the globe are required. Trisomy 21 in addition to its association with anorectal malformation has also been reported to be associated with imperforate anus and polydactyly (Gupta et al., 1998), Klinefelter syndrome (Rajangam et al., 1996, Cyrus et al., 2005),

Hypospadias with scrotal transposition (Yamaguchi et al., 1989) suggesting there by that trisomy 21 is responsible for wide spectrum of congenital anomalies.

In the present study all the four cases of trisomy 21 were born to mothers below 30 years of age thus ruling out the influence of maternal age in the present cases. All the 4 cases of Anorectal Malformation having trisomy 21 were 1st in birth order. The parents of these children were subjected to chromosome study for the analysis of their Karyotype and all the 4 couples were found to have normal karyotypes thus ruling out the carrier status of the parents in the 4 cases of trisomy 21. The present findings are in confirmatory with the earlier report ruling out the carrier's status of the mothers for the birth of typical Down syndrome. All the 4 cases of anorectal malformation showing trisomy 21 were from the families with no history of any congenital anomaly. Thus these 4 cases may be treated as sporadic one.

#### ACKNOWLEDGEMENTS

The authors are highly thankful to J&K State council for Science & Technology, J&K State and the Department of Zoology Kurukshetra University, Kurukshetra for extending liberal support to carry out the present work on the patients of 2 different states, J&K and Haryana.

#### REFERENCES

- Black CP, Sherman JO (1989). The association of low imperforate anus and Down's syndrome. *J. Pediatr.*, 24: 92-94.
- Cho S, Moore SP, Fangeman T (2001). One hundred three consecutive patients with Anorectal Malformations and their associated anomalies. *Arch. Pediatr. Adolesc. Med.*, p. 155.
- Cyrus C, Chandra N, Jegatheesan T, Chandralekha K, Ramesh A, Gopinath PM, Marimuthu KM (2005). Down Syndrome child with 48,XXY,+21 Karyotype. *Int. J. Hum. Genet.*, 11(1): 101-105.
- Gupta S, Gupte S, Raina TR, Gandotra A, Mehta V (1998). Imperforate anus and ploydactyl in a male Down Syndrome. *J. Cytol. Gent.*, 33(2): 207-209.
- Hassink EA, Rieu PN, Hamel BC, Spberijnen RSVD, Staak FH, Festen C (1996). Additional Congenital Defects in Anorectal Malformations. *Eur. J. Pediatr.*, 156: 477-482.
- Jayalakshamma MM, Amudha S, Tilak P, Devi R, Rajangam S (2010). Cytogenetic Analysis in Down Syndrome. *Int. J. Hum. Genet.*, 10(1-3): 95-99.
- Levitt MA, Pena A (2007). Anorectal Malformation. *Orphanet J. Rare Diseases*. DOI:10.1186/1750-1172—33.
- Rajangam S, Verghese M, Tilak P, Thomas IM (1996). A 48,XXY,+21 – Down/Klinefelter Syndrome. *J. Clin. Genet. Tribal Res.*, 2: 126-129.
- Saebright M (1971). Rapid Banding Technique for Human Chromosome. *Lancet*, p. 971.
- Torres R, Levitt MA, Tovilla J, Rodriguez G (1998). Anorectal Malformations and Down's Syndrome. *J. Pediatr. Surg.*, 33(2): 194-197.
- Yamaguchi T, Hamasuna R, Hasui Y, Kitada S, Osada Y (1989). 47,XXY/ 48,XXY,+21 chromosomal mosaicism presenting as hypospadias with scrotal transposition. *J. Urol.*, 142: 797-798.