

Case report

**Sujatha S Reddy, Shwetha V, Pallavi Chauhan, Sahana K**

Department of Oral Medicine and Radiology, M S Ramiah Dental College and Hospital, Bengaluru, Karnataka, India.

**Abstract**

**Cornelia de Lange Syndrome (CdLS) is a rare congenital disease, characterized by psychomotor retardation associated with series of malformations . The main clinical features include delay in growth and development, hirsutism, structural anomalies in the limbs and distinctive facial characteristics. It affects both the physical and intellectual development of the child. Dental problems include: ogival palate, micrognathia, dental malalignment, delayed teething, microdontic teeth, periodontal disease and dental erosion produced by gastric reflux.**

**Keywords:** CdLS, facial features, contracted maxilla, copper beaten appearance.

**Introduction**

Cornelia de Lange first introduced the disease described above as a distinct syndrome in 1933, <sup>1</sup> although Brachmann had described a child with similar features in 1916. <sup>2</sup> CdLS is also known as Brachmann de Lange syndrome (BdLS) or Brachmann Cornelia de Lange syndrome and Typus degenerativus amstelodamensis. CdLS is relatively rare and affects between 1/10,000 to 1/ 60,000 neonates .<sup>3</sup>

It is characterised by facial dysmorphism, including low anterior hairline, arched eyebrows, synophrys, anteverted nares, maxillary prognathism, long philtrum, thin lips and 'carp' mouth, in association with prenatal and postnatal growth retardation, mental retardation and in many cases, upper limb anomalies.<sup>4</sup> Dental problems include ogival palate (20% associated palatal fissures ), under development of the mandible , dental malalignment, delayed tooth eruption , microdontic teeth , periodontal disease and dental erosion produced by frequent gastric reflux which can produce oesophagitis ,oesophageal stenosis and pulmonary problems.<sup>3</sup> The diagnosis of this disorder is based solemnly on clinical grounds and there are no biochemical or chromosomal markers.<sup>5</sup> In classical cases there is rarely any difficulty in making the diagnosis , but in mildly affected cases, it may be difficult to feel sure about the diagnosis .

**Case report**

A 12 year old male patient diagnosed with CdLS reported, with a chief complaint of irregularly placed teeth and wanted orthodontic correction for the same. History revealed that our patient was the only child of a non consanguinous marriage, born after full term by normal delivery, birth weight was 3000 gms. Both parents were clinically asymptomatic, with no positive history of any deformity in their respective families. After birth the child was noted to have poor general health and delayed milestones. The child was diagnosed with CdLS at 6 years of age. His general health was good without any cardiac or respiratory defects and on psychiatric evaluation patient scored 60 on the Stanford Binet IQ scale which fell into the interval of 50-69 suggestive of moderate mental deficiency. Behaviour findings showed that he was an introvert and loved to be alone, with low attention span. The patient was attending a special school for learning disabled.

During physical examination we recorded the following details:

Weight: 30 kgs	Pulse: 102 beats/ min
Arm span: 132.5cm	Height: 124.3 cm (stocky built)
Gait: Normal	Head circumference: 47.5 cm.

His facial features seemed dysmorphic ,and had thick curly scalp hair with bushy eyebrows meeting in midline (synophrys),long curly eyelashes, hypertelorism, long and

full philtrum and low front and and back hairlines. (fig. 1). His ears were low set and anteriorly placed and he had anteverted nostrils, a small nose, thin lips with downward turned angle of mouth. He had slight plagiocephaly and brachycephaly (fig.2.), short neck, limited elbow extension, 5th finger clinodactyly, and hirsutism (fig.3). Patient also had lower limb defect i.e. short and wide feet.

Oral examination revealed high arched palate and contracted maxillary arch (fig.4). There was delay in eruption of mandibular canines. Mild hypoplasia with respect to maxillary anteriors was noted. Oral hygiene was poor. 55 and 65 (maxillary left and right deciduous 2nd molar) was decayed.

On radiological examination, panoramic radiograph revealed generalised microdontia, unerupted maxillary and mandibular permanent canines.(fig 6). Lateral cephalogram revealed proclined maxillary anterior teeth. PA view revealed "copper beaten" appearance of skull signifying raised intracranial pressure. (fig. 5).Growth analysis done on Hand wrist radiograph ( Bjork, Grave and Brown index) revealed that around 85% of pubertal growth spurt is still to be expressed. Cephalometric analysis revealed presence of skeletal class I malocclusion. In the first dental visit no treatment was initiated and only familiarisation with dental clinic environment was done. In subsequent visits orthodontic treatment was planned. Oral prophylaxis was performed and oral hygiene instructions given. 55, 65 were restored with GIC. Pit and fissure sealant was done for 36, 46(permanent mandibular first molars).

## Discussion:

CdLS is a clinically and genetically heterogenous developmental disorder characterised by growth and mental retardation. Growth retardation is almost a universal finding in patients with CdLS and typically has a prenatal onset. Mental retardation in patients with CdLS is often severe, resulting in mean IQ of 53. Many patients also demonstrate autism like behaviour.<sup>6</sup> No gender based predilection has been reported, and no differences linked to maternal age or race has been described.<sup>7</sup> The majority of cases are sporadic and very few familial cases of CdLS have been reported.<sup>8</sup> Pedigree analysis of several families have demonstrated autosomal dominant inheritance with both maternal and paternal transmission. Multiple genes are considered to be responsible for CdLS, all of which are implicated in sister chromatid cohesion. Mutations in the NIPBL (Nipped-B homolog) gene on chromosome 5p13.1 account for approximately 50% of CdLS cases and have been shown to cause both mild and severe forms of the disease.<sup>9</sup>

The clinical features of CdLS vary widely among patients, ranging from the classic form, which is severe, to mild forms and including some individuals who have non-syndromic phenotypes but some form of mental retardation.<sup>10</sup> In spite of the differences in severity, the facial dysmorphisms have provided the most helpful features in establishing a diagnosis. In patients with a mild clinical presentation, the characteristic facial appearance may not develop until two to three years of age, while it is always present at birth in the severe form.<sup>11</sup> The principal clinical characteristics of this syndrome are the delay in growth and development, hirsute, anomalies in the structure of the limbs and distinctive facial characteristics.<sup>3</sup> At birth and during the length of their life, these patients present a weight and size inferior to that corresponding to their age. The intellectual coefficient is not over 50%.<sup>3</sup> Our patient was also of short stature (125.3cm) and underweight (30 kgs.) corresponding to his age. According to Stanford Binet IQ test he was found to be moderately mental deficient and was attending a special school for mentally retarded. Structural malformations primarily affect the ulnar aspects of the upper limbs and can range from severe reduction defects, with almost complete absence of the forearms, to small hands with fifth-finger clinodactyly and proximally placed thumbs. Our patient also had limited mobility of the elbow and fifth finger clinodactyly. The feet of our patient was short and wide. Ullrich(1950)observed short feet without any malformation of lower limb in his study.<sup>12</sup>

The craniofacial structures are greatly affected. The case we have described presents the principal clinical characteristics of this syndrome. The alteration in the development and growth of the maxilla implies the presence of dental malalignments. The mental deficiency in conjunction with motor deficit, dental malalignment, the type of diet and other factors, makes the presence of dental caries and periodontal problems are frequent in this type of patients. For this reason, development of the maxilla and the teeth, and the presence of pathology, should be monitored from early on, and implement the appropriate preventative or therapeutic methods.<sup>13</sup> Intraoral examination revealed poor oral hygiene, caries in relation to 65 contracted maxilla with crowding and proclination of upper anterior teeth.

Braddock et al. (1993) presented a review of the classic radiological features of CdLS which includes microcephaly, limb and digital anomalies and delayed skeletal maturation.<sup>14</sup> In our patient radiographs revealed unerupted mandibular canine though the patient is <sup>12</sup> year of age. Some dental abnormalities reported earlier include delayed eruption, spacing and macro- or microdontia. Yamamoto et al, have reported two cases with delayed tooth

eruption and microdontia, with one of these cases being a partial anadontia.<sup>8</sup> PA view of skull revealed prominent convolutional markings seen throughout the skull called as 'Copper beaten appearance' of the skull which may be associated with raised intracranial pressure in children. They may be normal if they are confined to the posterior calvarium and are subtle. This feature has not been reported with respect to this syndrome so far in the literature.

Preventative awareness in coordination with the paediatrician starting at infancy is necessary. Routine revisions every six months facilitate the changes in orofacial growth, detection of pathologies and strengthen the care of teeth at home.

Diagnosing classic cases of CdLS is usually straightforward. Diagnosing mild cases may however be challenging even for an experienced clinician. An increased awareness of this syndrome is necessary as it may result in an early diagnoses and a decrease in morbidity.

**Acknowledgement:**

We would like to acknowledge our Principal, Dr. B V Srinivas Murthy and our HOD, Dr. Yashoda Devi B K for their support and guidance.

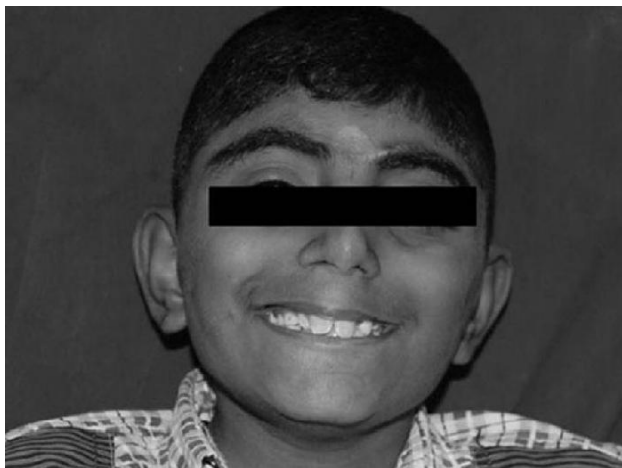

Fig 1 : Facial dysmorphism with low front hairline, synophrys, low set ears, anteverted nostrils, thin lips, long philtrum.

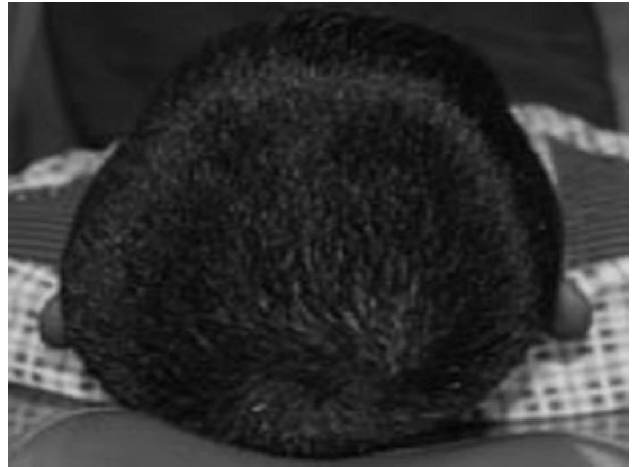


Fig. 2: Slight Brachycephaly and plagiocephaly

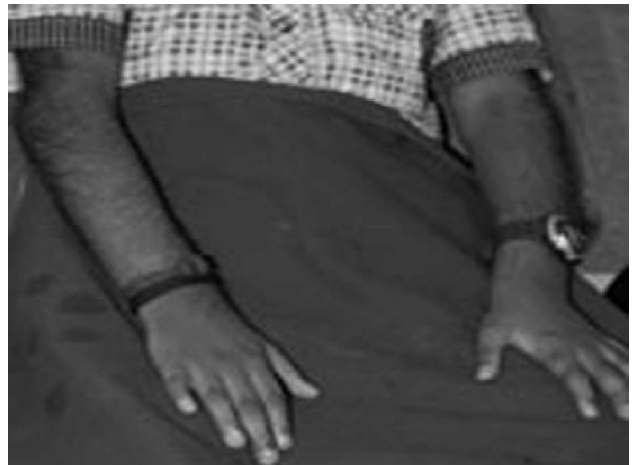

Fig. 3: Hirsutism, 5th finger clinodactyly.

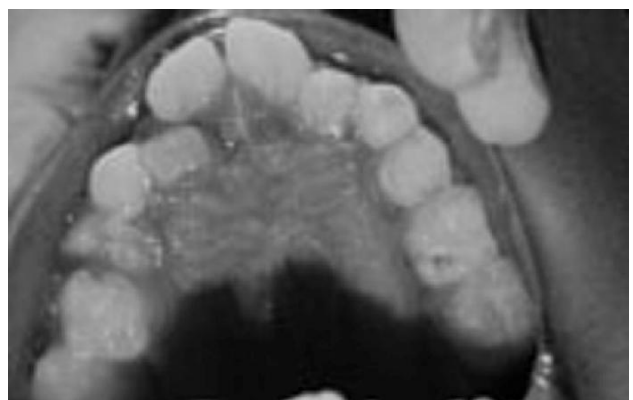


Fig. 4 High arched palate, crowding of upper anteriors.

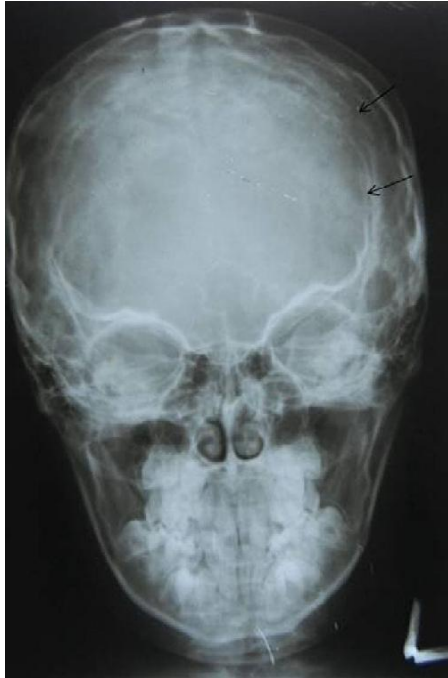

Fig 5: PA view showing “Copper beaten appearance” of the skull

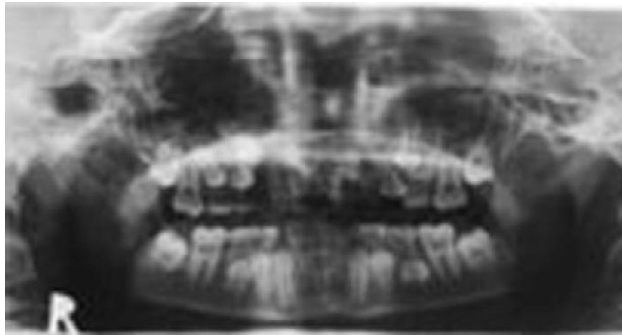


Fig 6: Orthopantomograph showing microdontia, delayed eruption of mandibular canines.

**References:**

1. Malik LM, Khan GA, Azfar NA, Jahangir M. Cornelia de Lange Syndrome - a cause of hypertrichosis in children: case report and of literature. *Journal of Pakistan Association of Dermatologists* 2011; 21 (3): 211-214.
2. Verma L, Passi S, Gauba K. Brachman de lange syndrome. *Contemp Clin Dent* 2010 ;1:268-70.
3. Carbó JC , Jiménez JL , Prats MJG , Molins MS. Cornelia de Lange syndrome: A case report. *Med Oral Patol Oral Cir Bucal.* 2007 Oct 1;12(6):E445-8.
4. Ambika L, Naik RB. Oral features in Cornelia De Lange syndrome. *IJBR* 2011;2(11) :575-8.
5. Musio A, Selicorni A, Focarelli M. L, Gervasini C, Milani, D, Russo S, et al. X-linked Cornelia de Lange syndrome owing to SMC1L1 mutations. *Nature Genet* 2006; 38:528-30. . 6. Galehdari H, Monajemzadeh R, Nazem H, Mohamadia G and Pedram M. Identification of a novel de novo mutation in the NIPBL gene in an Iranian patient with Cornelia de Lange syndrome: A case report. *Journal of Medical Case Reports* 2011, 5:242.

7. Barisic I, Tokic V, Loane M, Bianchi F, Calzolari E, Garne E, Wellesley D, Dolk H, EUROCAT Working Group: Descriptive epidemiology of Cornelia de Lange syndrome in Europe. *Am J Med Genet A* 2008, 146A:51-59.
8. Toker AS, Ay S, Yeler H, and Sezgin I. Dental Findings in Cornelia De Lange Syndrome. *Yonsei Med J* 50(2):289-292, 2009.
9. Gillis LA, McCallum J, Kaur M, DeScipio C, Yaeger D, Mariani A, Kline AD, Li HH, Devoto M, Jackson LG, Krantz ID: NIPBL mutational analysis in 120 individuals with Cornelia de Lange syndrome and evaluation of genotype-phenotype correlations. *Am J Hum Genet* 2004, 75:610-623.
10. Uzun H, Senses DA, Uluba M, Kocabay K: A newborn with Cornelia de Lange syndrome: a case report. *Cases J* 2008, 1:329.
11. Allanson JE, Hennekam RC, Ireland M. De Lange syndrome: subjective and objective comparison of the classical and mild phenotypes. *J Med Genet* 1997;34:645-50.
12. Ullrich O. Typus Amstelodamensis (Cornelia de Lange). *Ergeb Inn Med kinderheilk* 1951;2:454-58.
13. Jackson L, Kline AD, Barr MA, Koch S. de Lange syndrome: a clinical review of 310 individuals. *Am J Med Genet* 1993;47:940-6.
14. Braddock SR, Lachman RS, Stoppenhagen CC, Carey JC, Ireland M, Moeschler JB, et al. Radiological features in Brachmann-de Lange syndrome. *Am J Med Genet* 1993;47:1006-13.
15. Yamamoto K, Horiuchi K, Uemura K, Shohara E, Okada Y, Sugimura M. Cornelia de Lange syndrome with cleft palate. *Int J Oral Maxillofac Surg* 1987;16:484-91.